

Clinical Presentation of a 53-year-old female patient with greater trochanteric pain

John Morgan, SPT; Ethan Feder, PT, DPT, OCS, FAAOMPT; Peter Bowman, PT, DPT, FAAOMPT

Introduction

Greater trochanteric pain is a condition characterized by local tenderness to lateral hip which is exacerbated by prolonged weightbearing, direct pressure, activity, or falls.⁶ It is most-commonly related to gluteal tendinopathy.¹ It can have a profound negative impact on participation and activity levels.⁶ Neuropathic pain from the lumbar spine may present as lateral hip pain, and interventions for the spine may be necessary to address greater trochanteric pain.^{2,3,7}

Case Description

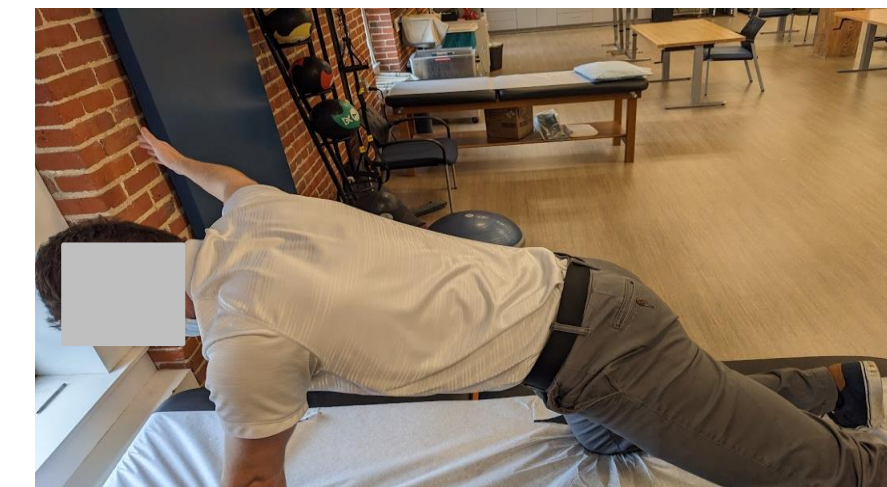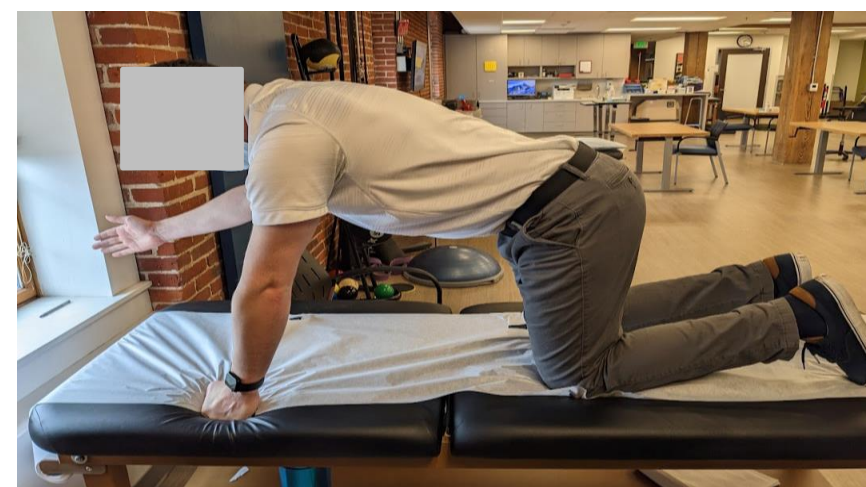
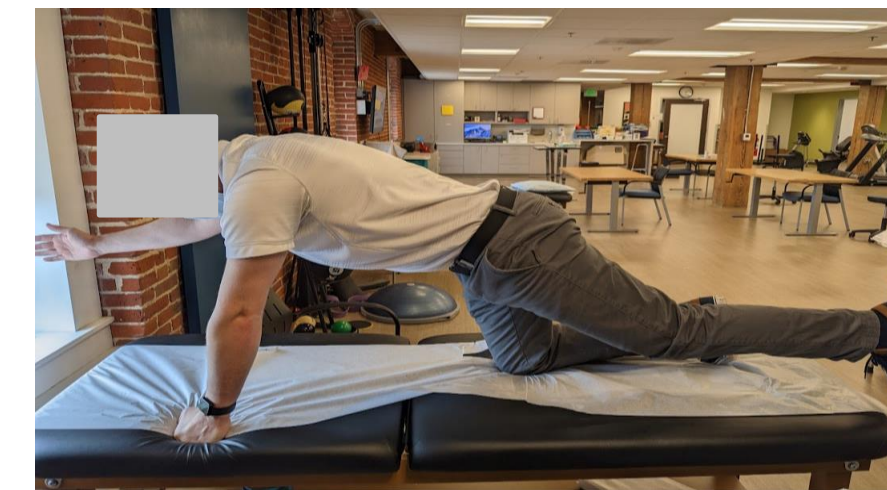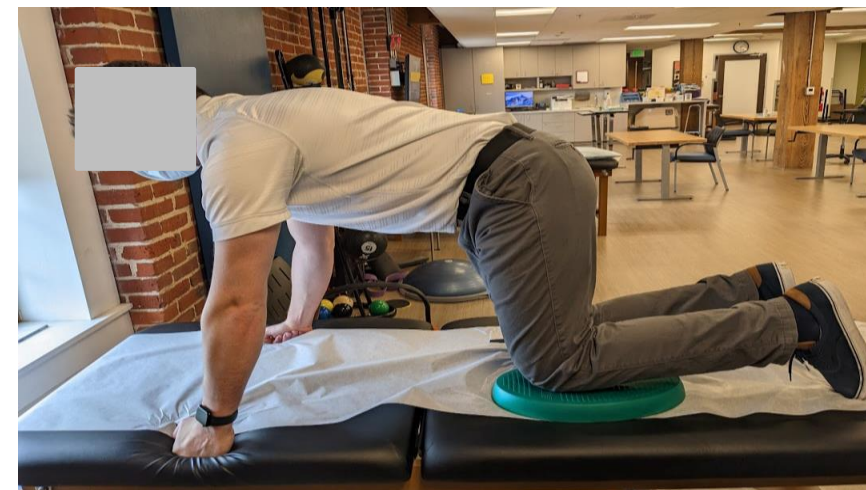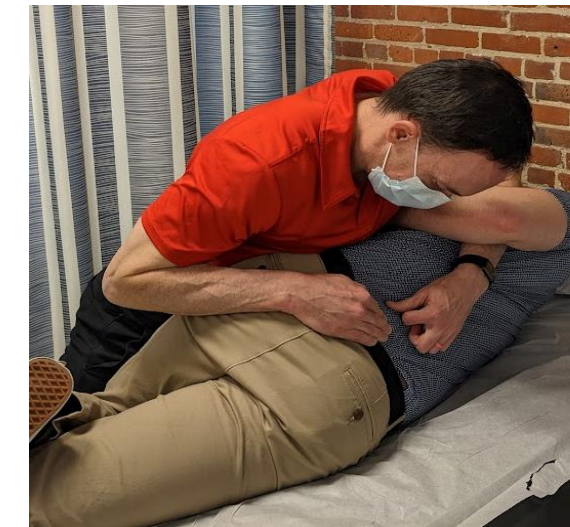- 53-year-old female with seven-month history of left (L) lateral hip pain radiating into her knee s/p fall from her bicycle
- Patient (pt) reported pain when entering/exiting bath, rising from deep squat, prolonged activity, especially walking/standing, and hand-heel rocking
- (+) tenderness to palpation at L greater trochanter, and pain radiating from L hip to L knee during quadruped hand-heel rocking
- (+) L FABER for posterior hip pain
- (+) L Resisted External Derotation for L lateral hip pain and weakness (3+/5)
- Unremarkable neurological examination: myotomes, dermatomes, and reflexes
- (-) Slump bilaterally
- (+) SLR at 50 deg with symptom reproduction at L hip radiating into knee
- Trunk extension and L sidebending limited and painful in her lower back (LB), and L hip, radiating into knee with extension
- Hypomobile PA L4-L5 and L5-S1 with localized pain
- Based on the above it was hypothesized that the patient had both nociceptive and neuropathic pain.

Purpose

Describe the clinical presentation and management of a patient presenting with symptomology consistent with concomitant greater trochanteric pain and lumbar radiculopathy.

Selected Interventions

- **Manual Therapy**
 - L lumbar facet gapping non-thrust manipulation
 - L4-L5 and L5-S1 Gr. III-IV
- **Neuromuscular Re-education**
 - Quadruped multifidus knee lifts
 - Quadruped multifidus arm raises
 - Quadruped bird dog with arm position variation



- **Therapeutic Exercise**
 - Supine glute bridge with band-resisted abduction isometric
 - Bodyweight box squat/ goblet box squat with band-resistance at knees
 - Band-resisted side-stepping
- **Therapeutic Activity**
 - Hand-heel rocking in pain-free range of motion

References

- ¹Bird PA, Oakley SP, Shnier R, Kirkham BW. Prospective evaluation of magnetic resonance imaging and physical examination findings in patients with greater trochanteric pain syndrome. *Arthritis Rheum.* 2001;44(9):2138-2145.
- ²Chamberlain R. Hip Pain in Adults: Evaluation and Differential Diagnosis [published correction appears in *Am Fam Physician.* 2021 Mar 1;103(5):263]. *Am Fam Physician.* 2021;103(2):81-89.
- ³Grimaldi A, Fearon A. Gluteal Tendinopathy: Integrating Pathomechanics and Clinical Features in Its Management. *J Orthop Sports Phys Ther.* 2015;45(11):910-922.
- ⁴Liang HW, Hou WH, Chang KS. Application of the modified lower extremity functional scale in low back pain. *Spine (Phila Pa 1976).* 2013;38(23):2043-2048.
- ⁵Reiman MP, Goode AP, Hegedus EJ, Cook CE, Wright AA. and Diagnostic accuracy of clinical tests of the hip: a systematic review with meta-analysis. *Br J Sports Med.* 2013; 47: 893–902.
- ⁶Speers CJ, Bhogal GS. Greater trochanteric pain syndrome: a review of diagnosis and management in general practice. *Br J Gen Pract.* 2017;67(663):479-480.
- ⁷Williams BS, Cohen SP. Greater trochanteric pain syndrome: a review of anatomy, diagnosis and treatment. *Anesth Analg.* 2009;108(5):1662-1670.

Outcomes (8 sessions over 9 weeks)

Outcomes were assessed with the Lower Extremity Functional Scale (LEFS), due to its high test-retest reliability and high correlation with Rolland-Morris Disability Questionnaire, Resisted External Derotation due to its high Sp and Sn at detecting presence of gluteal tendinopathy, and Hand-Heel Rocking due to patient reports of pain and utility for measuring within-session progress.^{4,5}

LEFS

From 69/80 to 78/80 = $\Delta + 9$

Resisted External Derotation

(-) L lateral hip pain by session 5
 Δ 3+/5 strength to 5/5 strength by session 8

Hand Heel Rocking

End range pain abolished by session 6

Discussion

Lumbar gapping and stabilization led to reduced symptom reproduction with provocative positions and functional activities, increased pain-free lower extremity and trunk range of motion, and improved hip strength, in addition to subjective reports of improved function. For patients medically diagnosed with greater trochanteric pain, the lumbar spine should be considered as a potential contributing factor.