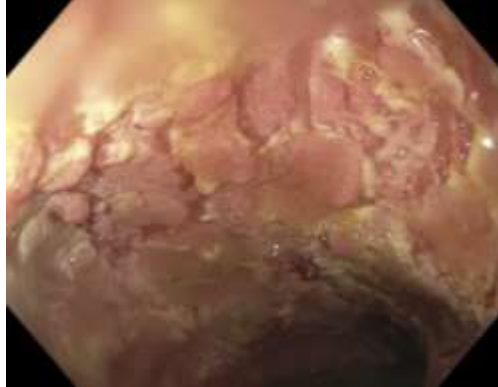

Session II: Case Discussion “The Pouch Board”

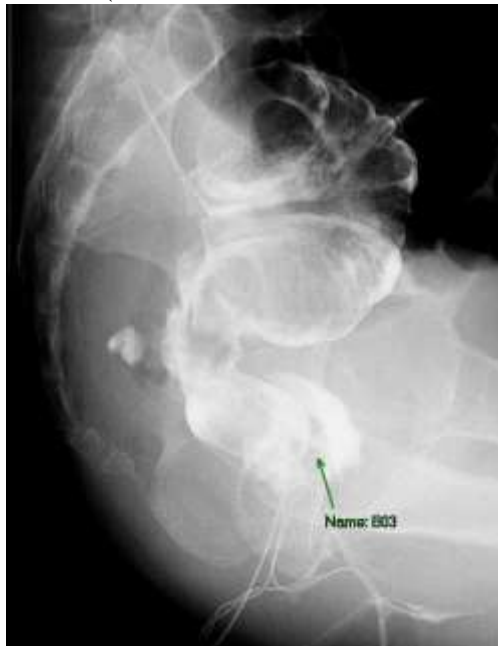
3:35PM – 5:15PM

Panelists: See attached table

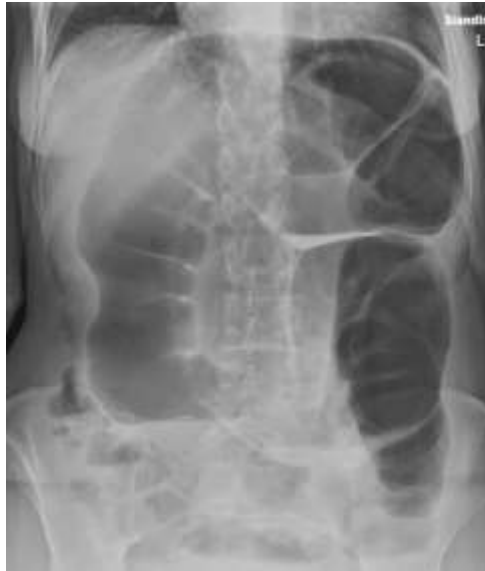Case 1. A 22-year-old male patient with severe pouchitis
(*Nan Lan, MD, PhD, Columbia University*)



Case 2. A 36-year-old female with presacral sinus and vaginal fistula. (*Bo Shen, MD, Columbia University*)



Case 3. A 61-year old female with twisted pouch and presacral sinus (*Kevin Lin, MD, Columbia University*)



Case 4. A 15-year-old boy with primary sclerosing cholangitis and pouchitis and enteritis (*Joseph Picoraro, MD, Columbia University*)

